

Evaluation of Modified Dorsonasal Flap for Reconstruction of Dorsonasal Defect in Erbil

Elza Faiz Hanna*

Sabir Osman Mustafa**

Abstract

Background and objectives: nasal reconstruction is challenging for plastic surgeons mainly because its midfacial location and the relationship between convexities and concavities of nasal subunits that make it difficult to hide any contour deformity; as a result, proper planning of final scar location is crucial for successful aesthetic outcome. The modified dorsal nasal flap is used for resurfacing nasal tip defects with respecting of these nasal subunits. This paper evaluates the outcome of modified dorsonasal flap for reconstruction of the dorsal nasal defects.

Method: in our department twenty nasal defects were reconstructed with modified dorsal nasal flap between years (2016-2019); Charts of these patients were analyzed in relation to their age, cause and size of the defect, complications and appearance.

Results: half of patients who underwent nasal reconstruction by dorsal nasal flap were males (n=10) and the other half were females (n=10), mean age 39.5 months, median defect diameter was (21mm), follow up period ranged from (7-42 months), all patients were satisfied with results with no significant complications including: hematoma, infection, flap loss or wound dehiscence.

Conclusion: Dorsal nasal flap is reproducible one stage flap for reconstruction of nasal defects with minimal complication and good aesthetic outcome.

Keywords: Nasal reconstruction, Flap, Basal cell carcinoma, Squamous cell carcinoma, Reiger's flap.

* M.B.Ch.B., KBMS trainee in plastic surgery, Erbil center.

Department of plastic surgery, KBMS, Erbil, Iraq

**M.B.Ch.B., HDGS, FIBMS (plastic)., Assistant professor in Hawler medical university.

Corresponding author: Elza Faiz Hanna. Email: elza.antwan26@gmail.com

Introduction

The nose is extremely important anatomical and aesthetic region given its role in social interaction. Nasal defects can occur as a result of infection, trauma, and congenital anomaly but mostly because of malignancy as the nose is considered the most common site of skin cancer in the head and neck^{1,2}. Options for addressing nasal defects are many include; primary closure, healing by secondary intention, skin graft, local and regional flaps³⁻⁵. Optimal results are obtained when “like is used to repair like” by using local flaps to recruit adjacent tissue to the defect as it has the same color and texture of the area and also flaps are regarded to be the best option in the presence of full thickness defects^{6,7}. The dorsal nasal flap is a local flap that can be used to reconstruct nasal skin defects in single procedure leading to decreased risk to the patient with increased convenience; and yet it’s a very versatile flap that can be modified or combined with other local flaps to close even bigger defects⁸. The procedure involves rotational advancement of dorsal

nasal skin from glabella and upper two-third of nose to cover a defect of the distal nose and the secondary defect will be closed primarily in most cases resulting in a scar that is well camouflaged^{9,10}. The flap was originally described in 1967 by Rieger as a random pattern rotational flap used to cover tip defects up to 2 cm in diameter¹¹. In 1970 this flap was modified by Marchac to an axial pattern flap based on a branch of angular artery which resulted in a narrowed pedicle increased mobility of the flap¹². In 1993 de Fontain et al. proposed a modification to Marchac’s flap (for lateral tip defects) by placing the flap base ipsilateral to the defect, thus avoiding a scar across the dorsum¹³. Rohrich in 1999 suggested that the glabellar incision is not necessary and they used a transverse incision in the radix crease¹⁴. Our aim from this study is to assess the outcome of modified dorsonasal flap for reconstruction of the nasal dorsum according to: scar appearance, flap viability and extent of coverage.

Patients and method

This study was done in Rizgary Teaching Hospital; between March, 2016 to May, 2019, twenty patients were recruited from plastic and reconstructive surgery

department. Patients who met the following criteria were included in the study: any dorsal nasal defect in mid and lower third of nose. We excluded patients who have

previous scar on glabella and patients with poor compliance for follow-up. Informed consent was collected from all patients for participation and verbal consent was taken for photograph publishing. The procedure was done under local or general anesthesia according to patient's preference and comorbidities. For creation of the flap a curvilinear incision from lateral edge of the defect was made along nose-cheek groove to the ipsilateral inner canthus and angled to the center of the glabella, and then the incision is angled down into contralateral inner canthus to allow proper transposition while maintaining adequate blood supply (Figure1). The flap is elevated by undermining beneath the musculature of nose until the entire flap is lifted off the

periosteum and perichondrium. After meticulous hemostasis the flap was transposed, trimmed and sutured in position with 4-0 buried polyglycolic acid for deep dermal approximation and 5-0 or 6-0 interrupted polypropylene sutures placed to approximate the epidermis. To eliminate dog-ears, excision of Burrows triangles is done parallel to ipsilateral alar groove. The wound is cleaned, dried and dressed with topical antibiotic ointment, gauze and adhesive tape. Postoperatively the patient is sent home within five hours. Sutures are removed between fifth and seventh postoperative day and the patient is seen at 1 week, 6 weeks and then every three months for one year (Figure 2).

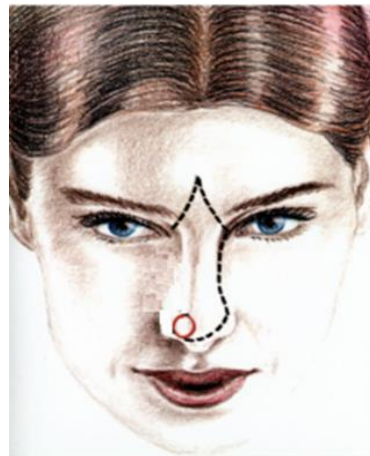
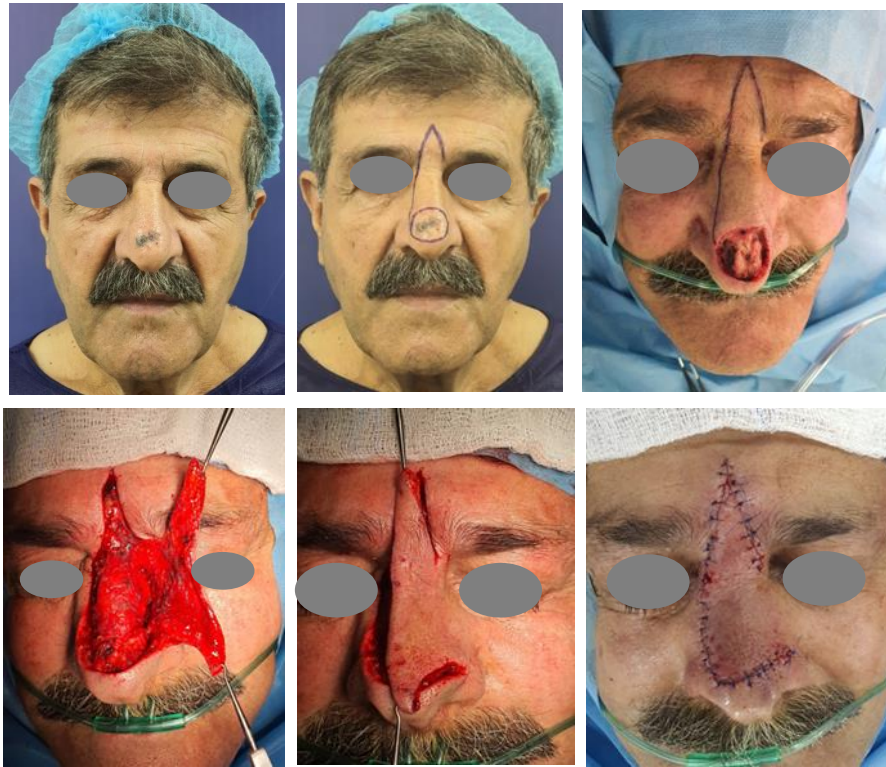

Figure (1). Marking of modified axial flap by De – fontaine ¹⁵



Figure(2). Steps of surgical procedure for dorsal nasal flap, A: Patient with Basal cell carcinoma BCC on tip of the nose B: Pre-operative marking, C: After excision of skin tumor, D: Elevation of flap, E: Flap inset, F: Immediate post-operative picture.

The study was approved by the ethical committee of Kurdistan Board for Medical Specialties

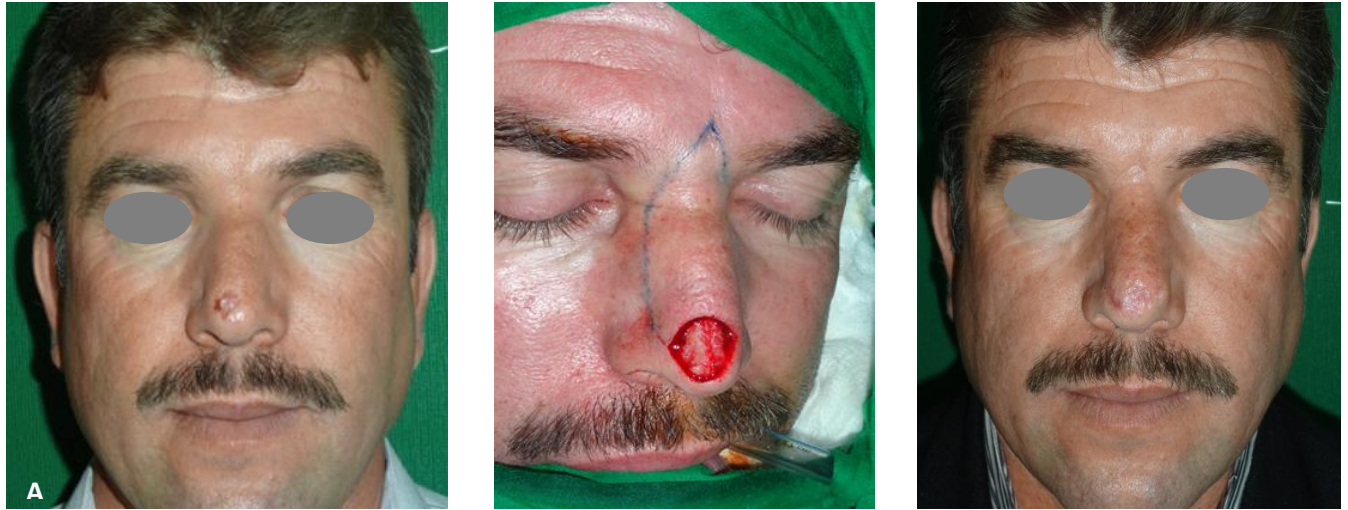The statistical method used was independent sample t-test, $p\text{-value} \leq 0.05$ was considered significant

Results

Twenty reconstructions were performed for nasal tip or supranasal defects, from those half of the patients were male ($n=10$) and the other half were female ($n=10$), mean age was 59 years (range 37-72). The defects resulted from basal cell carcinoma ($n=14$), squamous cell carcinoma ($n=3$), recurrent basal cell carcinoma ($n=2$) and leishmania

scar ($n=1$). The median defect diameter was 21 mm, the smallest defect measured (15×13 mm) and the largest measured (27×24 mm). The follow up ranged from seven months to three and a half years, all the patients were satisfied with the results, there were no instances of post-operative

hematoma, infection, flap loss or wound dehiscence. (Figure 3)



Figure(3). A: Patient with basal cell carcinoma of nose. B: After excision of lesion. C: Six months after reconstruction with dorsal nasal flap.

We used independent sample t-test and there was a statistically significant difference between width and length of defect in

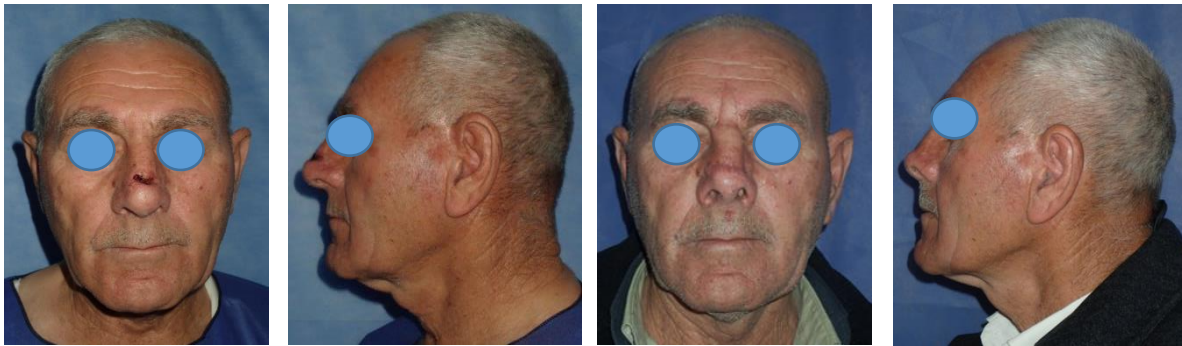
millimeter of operated cases in regard to Tip elevation p-value < 0.05. (Table 1 and Table 2), as shown in Figure(4).

Table(1). Difference of mean width between operated cases in relation to tip elevation.

Difference of mean width between operated cases					
	Tip Elevation	No.	Mean in mm	Std. Deviation	p- value
width	Yes	4	23.5	0.57	< 0.001
	No	16	19.3	3.65	

Table(2): Difference of mean length between operated cases in relation to tip elevation.

Difference of mean length between operated cases					
	Tip Elevation	No.	Mean in mm	Std. Deviation	p-value
Length	Yes	4	26.5	1.0	< 0.001
	No	16	21.2	3.6	



Figure(4). A & B: Pre-operative frontal and profile view of patient with basal cell carcinoma of nose C & D: Post-operative result (frontal and profile of the same patient) showing tip elevation.

Discussion

Nose is a central aesthetic unit of the face and the subunits of the nose have been defined as dorsum, tip, alae, sidewalls and soft triangles¹⁶. The nasal reconstruction is regarded challenging as it is a three dimensional structure with different components of mucosal lining, cartilage, bone and skin. The subunit approach to nasal reconstruction allows the correctly located scars to mimic the normal shadows of nasal surface in order to restore the contour¹⁷.

The majority of cases of nasal defects are from cutaneous malignancies in elderly patients with multiple comorbidities; these patients frequently prefer single stage reconstruction; the reconstructive options range from primary closure to skin graft and flaps and even free tissue transfer, depending on size, site and the layers that are involved. Skin grafts is the simplest way and it's easy to perform but even the full thickness type yield aesthetically

unpredictable results and has a patch like appearance with need for many sessions of dermabrasion afterward¹⁸. Variable local and regional flaps have been described for reconstruction of tissue defects of nose but most of these flaps present a number of disadvantages from which distortion of nasal profile and creating scars that lie within the aesthetic subunits. Regional flaps like paramedian forehead flap is a very good option for nasal reconstruction but needs at least two operations (two weeks apart) in the meantime the patient have to take time off work and withdraw from social interactions that's why its reserved for resurfacing very big nasal defects. Dorsal nasal flap can be based medially or laterally, if large amount of rotation is needed, the pedicle can be narrowed for greater degree of motion, in addition to wide undermining sometimes cephalic trim of lower lateral cartilages and lowering of dorsal hump in very big noses can aid in motion of flap to cover even bigger defects, and the skin edges should be carefully thinned to approximate that of recipient area; so that the skin texture, consistency and color of the flap will match perfectly with the surrounding defect. This flap doesn't have "pincushioning" effect that is often seen in bilobed flap¹⁹, there is no distortion of nose as result from banner flap,

its one stage procedure that allow the patient a quick return to work; and the glabellar scar is well hidden in vertical furrows of brow²⁰. Moreover, it doesn't harm the forehead donor site, which may be essential if there is need for second reconstruction after tumor recurrences or late appearance of new tumors arising in the same area. Although originally described for partial thickness defect, dorsal nasal flap can be used in full thickness defects and has been noted that multilayer reconstruction with using dorsal nasal flap has several advantages over reconstruction that used forehead flap, cartilage grafts, and vestibular lining flap⁷. The flap has a good axial blood supply by dorsal nasal artery which is a terminal branch of ophthalmic artery; it perforates the orbital septum just above medial canthal ligament and runs down along the nasal bones just above the fibro-muscular layer. It has many anastomoses with angular artery, alar branch of facial and superior labial artery; and it also communicates with the adjacent dorsal nasal artery across the midline²¹⁻²³. The key for successful results when using dorsal nasal flap are the following: (1) proper selection of nasal defects (2) meticulous planning and execution of the flap (3) hemostasis of the wound bed (4) precise thinning and

trimming of flap edges (5) closure by everting the skin edges¹⁴. We used dorsal nasal flap modification by de fontaine et al, who applied the subunit principle by using

Conclusions

Dorsal nasal flap is a versatile and straightforward single stage rotation-advancement flap, easy to learn and perform by surgeons with a reliable blood supply,

Conflict of interests

The authors recorded no conflict of interests.

References

1- Kang KW, Lee DL, Shin HK, Jung GY, Lee JH, Jeon MS. A retrospective clinical view of basal cell carcinoma and squamous cell carcinoma in the head and neck region: a single institution's experience of 247 cases over 19 years. *Arch of Craniofac Surg.* 2016 ;17(2):56.

2-Choi JH, Kim YJ, Kim H, Nam SH, Choi YW. Distribution of Basal cell carcinoma and squamous cell carcinoma by facial esthetic unit. *Arch of Plast Surg.* 2013; 40(4):387.

3-Bieniek A, Matusiak Ł, Chlebicka I, Szepietowski JC. Secondary intention healing in skin surgery: our own experience and expanded indications in hidradenitis suppurativa, rhinophyma and non-melanoma

ipsilaterally based pedicle in repairing lateral defects and placement of inferior incision in alar crease which resulted in scar lines that are minimally visible¹³.

low complication rate and excellent cosmetic results and we recommend its use in defects less than 20mm diameter in mid or lateral nasal tip

skin cancers. *JEADV.* 2013; 27(8):1015-21.s

4-Olander J, Wong M, Brown M. Use of a Single Anatomic Donor Site for Harvesting a Full-Thickness Skin Graft and a Free Cartilage Graft for Nasal Defects. *Dermatol. Surg.* 2018 ;44(7):1023-4

5-Salgarelli AC, Bellini P, Multinu A, et al. Reconstruction of nasal skin cancer defects with local flaps. *J. Skin Cancer.* 2011;2011.

6-Cox A, Fort M. Nasal reconstruction involving multiple subunit defects. *Facial Plast Surg.* 2017 ;33(01):58-66.

7-Vishnoi JR, Misra S. Loco regional flaps a boon for Surgeons in Head and Neck Reconstruction even in the Era of Microvascular flaps. *Indian J. Surg. Oncol.* 2019:1-2.

- 8- Eren E, Beden V. Beyond Rieger's original indication; the dorsal nasal flap revisited. *J Craniomaxillofac Surg.* 2014 ;42(5):412-6.
- 9- Jena A, Gangasani R, Reddy N, Patnayak R. Reconstruction with dorsal nasal flap after excision of basal cell carcinoma of the nose. *J Cutan Aesthet Surg.* 2017;10(1).
- 10- Lu GN, Kriet JD, Humphrey CD. Local cutaneous flaps in nasal reconstruction. *Facial Plast Surg.* 2017 ;33(01):27-33.
- 11- Rieger RA. A local flap for repair of the nasal tip. *Plast Reconstr Surg.* 1967;1;40(2):147-9.
- 12- Marchac D. Lambeau de rotation frontonasal. *Ann. Chir. Plast.* 1970; 15:44-9.
- 13- De Fontaine S, Klaassen M, Soutar DS. Refinements in the axial frontonasal flap. *Br J Plast Surg.* 1993; 46(5):371-4.
- 14- Rohrich RJ, Muzaffar AR, Adams JW, Hollier LH. The aesthetic unit dorsal nasal flap: rationale for avoiding a glabellar incision. *Plast Reconstr Surg.* 1999; 104(5):1289-94.
- 15- Parodi PC, De Biasio F, Cordaro ER, Candiani M, Riberti C. Frontonasal myocutaneous flap based on the transversus nasalis muscle. *Plast Reconstr Surg.* 2005 ;115(6):1684-8.
- 16- Larrabee YC, Phillips DJ, Sclafani AP. Trends in nasal subunit reconstruction by facial plastic and reconstructive surgeons. *Facial Plast Surg.* 2017; 33(01):017-9.
- 17- Aldosari BF. The Axial Frontonasal Flap for Nasal Tip Defect: A Single Centre Experience. *Cureus.* 2019 ;11(10).
- 18- McCluskey PD, Constantine FC, Thornton JF. Lower third nasal reconstruction: when is skin grafting an appropriate option? *Plast Reconstr Surg.* 2009 ;124(3):826-35.
- 19- Kemler MA. Two-Year Evaluation of Either Bilobed Flap or Full Thickness Skin Graft as a Closure Technique of the Nasal Tip. *J Dermatol Res Ther.* 2016; 2:038.
- 20- Bitgood MJ, Hybarger CP. Expanded applications of the dorsal nasal flap. *Arch Facial Plast Surg.* 2007 ;9(5):344-51.
- 21- Manchot C. *The cutaneous arteries of the human body.* Springer; 2013.
- 22- Niemann K, Lazarus L, Rennie C. An Anatomical Study of the Facial Artery. *Int J Morphol.* 2019 ;37(4).
- 23- Pisl U, Anderhuber F. The external nose: The nasal arteries and their course in relation to the nasolabial fold and groove. *Plast Reconstr Surg.* 2016;138(5):830e-5e.