



Evaluation of perforator flap for soft tissue reconstruction of distal leg and foot

Hemin Aladden Saeed*

Madhar Ali Amin**

Abdulrahman Baiz Abdulrahman***

Abstract

Background and objectives: Reconstruction of soft tissue defect of the distal leg and foot regarded as a major task in plastic reconstructive surgery, durable coverage of such defect is usually needed. Using of local flap based on single perforator raising interest for reconstructive surgeon to reconstruct leg. The aim of study is to evaluate the versatility of perforator flap for reconstruction of the soft tissue defect in distal leg and foot according to: donor sit morbidity, flap viability and extent of coverage.

Method: This is prospective study conducted in KRG (Kurdistan region government) of Iraq, twelve patient involved in this study, seven of them are males (n=7) and the other were females (n=5), mean age 31 years (8-62), with soft tissue defect mean (5.8-14.5cm), defect where located in distal leg in eleven patients and two located in foot, all defects was due to road traffic accident treated with perforator flap (one patient both legs operated).

Results: in this study twelve patient involved and thirteen procedure done for them, in eight out of thirteen procedures the flap survived totally without complication 61.5%, in one patient flap is totally lost 7.7%, while in other develop complication in form of partial necrosis in three cases 23.1% and flap congestion in one case.

Conclusion: The perforator flap is reliable flap for soft tissue reconstruction of distal leg and foot and can replace free flap in our practice in selected cases.

Keywords: Perforator flap, Propeller flap, Lower limb, Reconstruction

* M.B.Ch.B. Erbil-Iraq. Rizgary Teaching Hospital. E-mail: hemnaladden@yahoo.com

** FIBMS (Plastic surg.).

*** FIBMS (Plastic surg.). Rizgary teaching Hospital, West Emergency Hospital and private hospital(PAR) in Erbil-Iraq.

Introduction

Lower limb (leg & foot) reconstruction is one of the most difficult task to reconstruct to plastic surgeon, Soft tissue loss of leg especially lower one third of leg and foot lead to exposure of neurovascular structure, bone and joint, which mostly need coverage by flap, tight skin envelopes in this area limit local flap in this area¹⁻¹³. A free flap is often recommended to repair the wound in distal leg and foot with exposed bone, tendon, and neurovascular structure that need flap for coverage, limitation of availability of soft tissue for reconstruction in this area made free flap to be the first choice but this is extremely time consuming and requires years of training and experience⁴⁻⁵. Surgeon's before era of microsurgery they have few options for reconstruction of leg like skin graft, local flap or cross leg flap⁶⁻⁷. The propeller flap was first described in 1991 by Hyakusoku et al., for reconstruction of the axillary and cubital defect after post burn scar contracture release by factiousness

Materials and methods.

From October 2016 to December 2018, 12 patients were treated with perforator-based propeller flap for coverage of soft tissue in distal leg and foot defects (Table 1). seven

flap rotated 90 degrees to cover the defect⁸⁻⁹. The perforator flap is based on the concept that skin, sub-cutaneous fat and deep fascia is nourished by perforator vessels that arise from a deep vascular system which reach the skin through either muscle which is more common or directly through inter muscular septum^{4,9}. Information regarding the anatomy of perforator all over the body increased the era of using perforator flap, for reconstruction of the defects of all the body^{9,12}, Color Doppler or small handheld Doppler is very helpful for preoperative evaluation of pedicle and planning of flap¹⁰⁻¹¹. Perforator flap have many advantages in this technique you will replace like by like tissue with superior aesthetic and functional outcome, the ability to completely or partially close the donor site, wound remain in the same area of operating site, no need for microvascular anastomosis, decrease operative time when comparing with free flap, High flexibility and arch of rotation^{5,7}.

were male and others female. Mean \pm SD age was 33 ± 19 years. All defects were posttraumatic due to road traffic accidents. One patient had bilateral wound two

procedure done for him, no history of any comorbid conditions in any cases. Seven patients presented with defect over anterior aspect of lower tibia, three patients presented with defect over Achilles tendon, one distal fibulae defect and two patients presented with defect in dorsum of foot. Size of defects ranged from 6×4 to 10×9 cm. The flaps were based on posterior tibial artery in 5 patients, peroneal artery in 6 patients and anterior tibial artery in two cases. All flaps were islanded on a single perforator. Preoperatively design of flap is started by detecting a perforator near the defect with the aid of hand-held Doppler probe 8Mhz and marked, Concept of propeller flap corresponds to two limbs of propeller of unequal length (long limb and short limb) long limb proximal to the perforator and short limb distal to it and perforator forming the pivot point of our flap (Figure 1). When The two limbs rotated, the long limb fills the defect. The distance between proximal tip of the flap and the perforator should be equal to the distance between the perforator and the distal limit of the defect plus 2cm to prevent

tension in the flap during inset. Surgical technique: The patient is positioned supine; the flap was drawn adjacent to the defect around the perforator. A tourniquet is inflated without exsanguination; this approach helps us to identify perforators easily as they remain filled with the blood. All flaps were dissected under loop magnification. An exploratory incision made along posterior margin of the flap from the skin till deep fascia. The dissection started in subfascial plane then deep fascia sutured with the skin to prevent suprafascial plexus injury during flap elevation, dissection continue till septum in which there are multiple perforators, keeping in mind the expected site of perforator. Once suitable perforator was found, dimension of the flap confirmed or changed according to the situation. Flap margins were then incised; all proximal perforators are ligated so as to island it on selected perforator. Adequate release of all fascial strands around the perforator and dissection around the perforator in intermuscular or intramuscular plane to gain additional length.

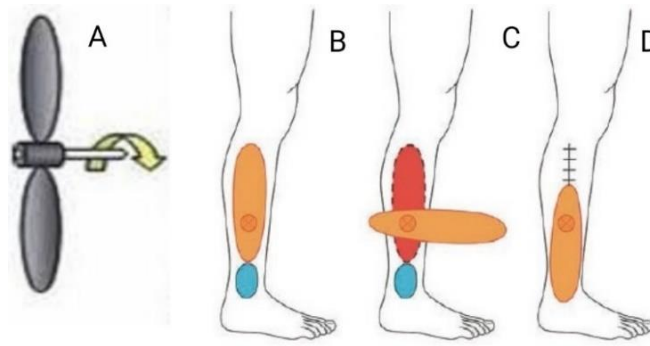


Figure (1): A, concept of perforator flap. B, flap design. C, flap rotation. D, flap inset and direct closure of donor site¹⁵.

This will facilitate rotation of flap without kinking the perforator, after deflation of the tourniquet, washing of pedicle by xylocaine, it's better to leave the flap in its original position for 10-15 minutes to allow its reperfusion and the perforator's spasm disappearance, hemostasis was performed and viability of the flap was evaluated. Finally, rotation of the flap as a propeller into the defect was performed and position of the perforator was once again checked to avoid kinking, the most common arc of rotation was 180° for propeller flaps ranging from 90° to 180°. The flap is inset and sutured into the defect. Proximal donor area

is closed either by primary closure or with skin graft (figure -2). Post operatively we followed up the patient in hospital for 48 hours and close observation of flap, vital sign specially blood pressure should be within normal range for perfusion of the flap and leg slightly elevated and internal rotation of leg in case of peroneal and anterior tibial artery perforator flap and external rotation in case of posterior tibial artery perforator flap, usually the patients are discharged after 48hours. the patients would be seen after one week, stich removed in second week and follow-up the patients every three months for two years.

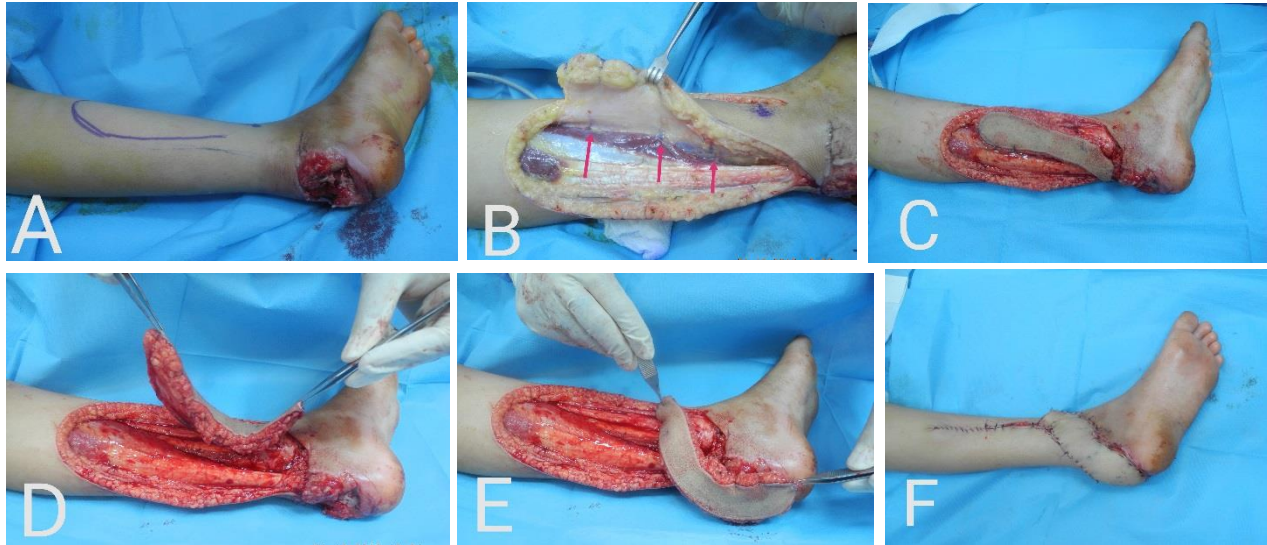


Figure (2): A, Design of flap. B, Incision in posterior flap margin and find perforators. C, Harvesting the peroneal artery perforator flap and totally islanding the flap. E, rotation of the flap to the defect. D, flap inset and direct closure of donor site.

Result

Total of twelve consecutive patients operated from October 2016 to December 2018 (one patient both legs operated) for distal leg and foot soft tissue defect reconstructions in private and governmental hospitals in KRG/ Erbil/ Iraq, the Mean \pm SD operative time was 141 \pm 51 minutes (range 90 to 190). In Eight patients (61.5%) flap survived totally without any complication 61.5%, and Complications happened in 38.5%, One patient (7.7%) developed total flap necrosis. Three patients (23.1%)

developed partial distal flap necrosis, which was managed with skin grafting, one patient (7.7%) developed venous congestion, which subsided spontaneously., about donor site four (30.7%) cases donor site closed by direct closure while other nine cases (69.2%) by skin graft. Nine patients were satisfied with the result (n=9) and four patients was not satisfied with the result (n=4), the demographic and clinical data for each patient are presented in (Table 1).

Table (1): Patient’s demography

Name	Gender /age	Flap size in cm	Defect size in cm	Source of perforator	Donor site closure	Complications
No 1	F/33	14*8	7x10	PA	<i>skin graft</i>	None
No2	M/40	19x8	10x7	PA	skin graft	None
No3	F/16	13x5	8x5	PA	direct closure	Distal congestion
No4	M/14	17x6	9x6	ATA	skin graft	Partial necrosis
No5	M/45	13x4	6x4	PA	direct closure	None
No6	F/9	16x6	5x5	PTA	direct closure	Partial necrosis
No7	M/19	19x10	17x9	PTA	skin graft	None
No8	M/60	17x5	8x4	PA	skin graft	Complete loss
		19x5	7x5	PA	Skin graft	Partial necrosis
No9	M/36	12x4	6x4	PTA	skin graft	None
No10	M/62	14x5	8x5	PTA	direct closure	None
No11	F/37	13x4	7x4	PTA	skin graft	None
No12	F/8	12x5	5x6	ATA	skin graft	None

Abbreviations used in table; F: female, M: male, PA: peroneal artery, ATA: anterior tibial artery, PTA: posterior tibial artery

Table(2): Flap’s complications

Complications	Frequency	Percent	Cumulative Percent
Complete loss	1	7.7	7.7
Distal congestion	1	7.7	15.4
Partial distal necrosis	3	23.1	38.5
Total	5	38.	

Discussion

Lower limb trauma is one of the most commonly facing problems by the reconstructive plastic surgeon, there are

multiple options for soft tissue reconstruction of lower extremity from locoregional flap to free flaps have been

described¹⁻³. Random flap usually used for small size defect and had limited flap size with wide base, faciocutaneous flap first described by ponten 1981 but it has drawback that cannot be rotated 180 degrees, large dog ear at it base with large donor site morbidity, mostly need skin graft for closure of donor site. Cross leg flap it is difficult for patient to stay in position for three weeks' especially adult patient difficult handling, Free flap which is ideal option for lower limb reconstruction but need long operation time and special instrument not suited for every patient. Distally based sural flap is a good option and has comparable result with perforator flap for this conditions of the lower limb but sometime the pedicle of sural flap injured during trauma so this option no longer available^{9,11}, this flaps are easier and technically less demanding than the propeller flap, However, these types of flaps produce 'dog ears' at the pedicle after flap rotation³. In our study we did perforator flap for leg and foot defect reconstruction with success rate more than 90%, complication happened in 5 flaps, one case developed

Clinical cases

Case 2: A 36-year-old man had a traumatic soft tissue loss of the lower leg with exposure of the Achilles tendon, radical

distal flap congestion which was treated conservatively, two patients developed distal flap partial necrosis, those cases was treated by wound debridement and skin graft. In one case the flap totally lost in which the patient had severe crush injury to the legs with bone fracture we did bilateral peroneal artery based perforator flap left leg flap completely lost and right leg partial necrosis which was most probably due to difficulty in positioning of the legs and tight flap inset. The largest flap in our study was 19cm x 9cm based on posterior tibial artery perforator while the largest flap in study done by Alexandru V. Georgescu was 28cm x 13 cm based on posterior tibial artery perforator⁴. Perforator flap have many advantages over free flap in selected cases, these include operative time, less hospital stay, less cost, replace like tissue with like, not sacrificing the major artery of leg, not sacrificing any muscle of leg, donor site within same filed of operation, sometime donor site can be closed directly, not required advanced microsurgical skills and equipments^{3,14}.

debridement done. To restore soft tissue coverage by peroneal artery-based perforator flap measuring 19 cm x 8 cm was harvested

and transferred to the defect. The donor site was closed split thickness skin graft, and the

transferred tissues survived completely (Fig.2).

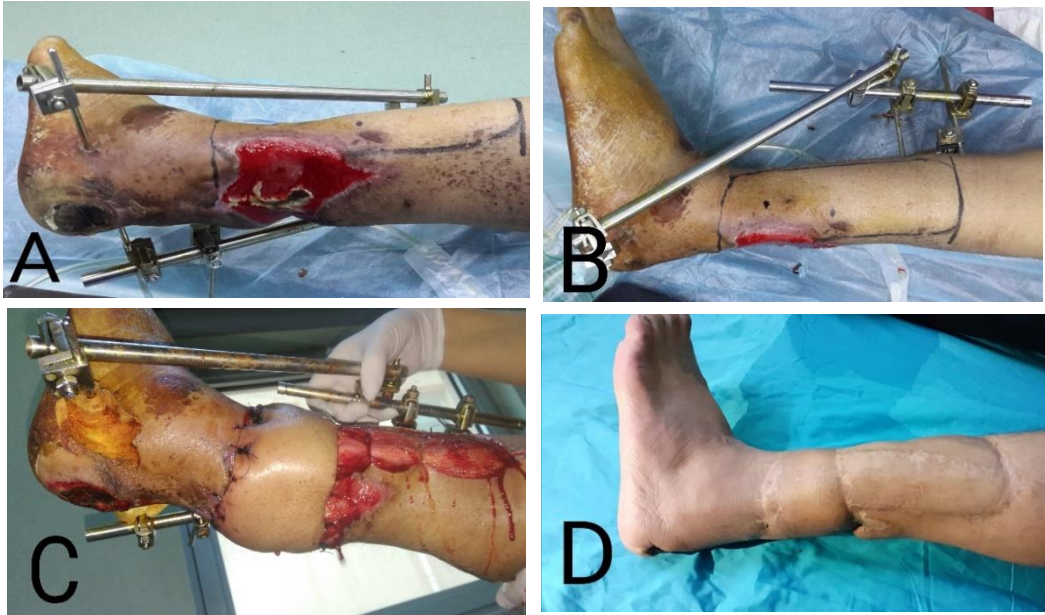


Figure (2): A, B A defect in distal leg posteriorly with exposed Achilles tendon. **C** Early postoperative view. **D** Appearance After another operation skin grafting of donor site. **F** Follow-up at 2 year's post operation.

Case 5: A 45-year-old man developed traumatic Achilles tendon exposure with a soft tissue defect after road traffic accident. After debridement of the necrotic tissue, a flap based on peroneal artery perforator flap measuring 4 cm × 13 cm was raised from

the same leg and transferred to the defect. The donor site was closed primarily. Postoperatively the flap survived totally without any complication, and the patient was satisfied with the appearance (Fig. 3).

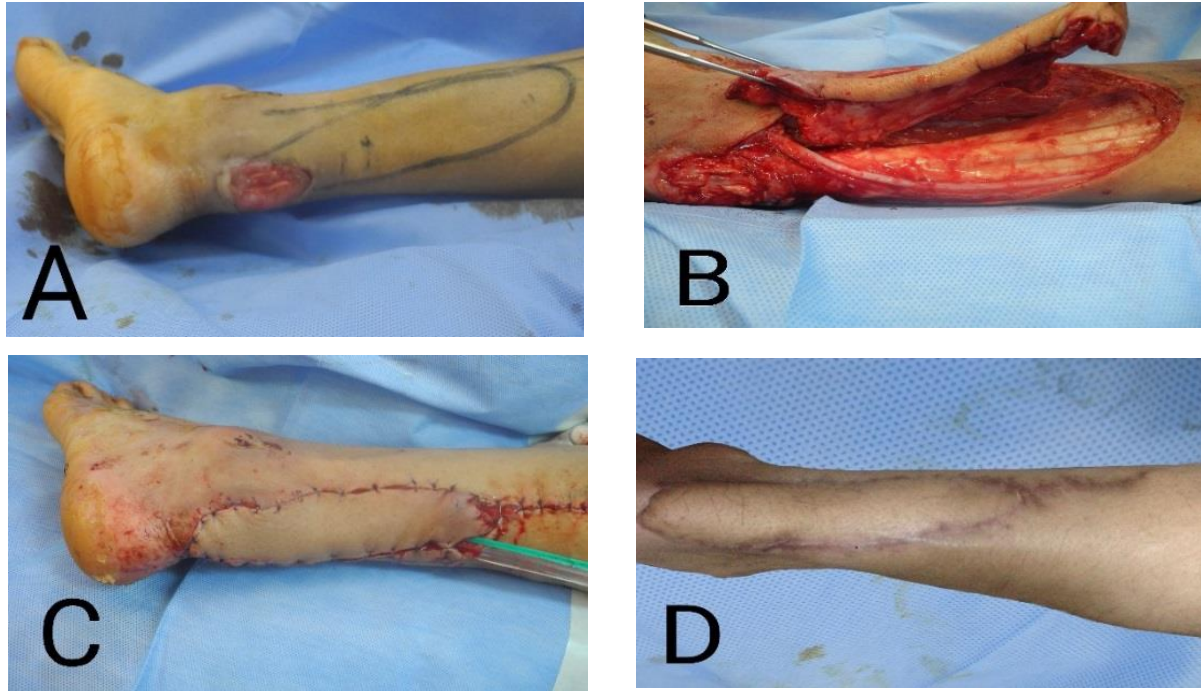
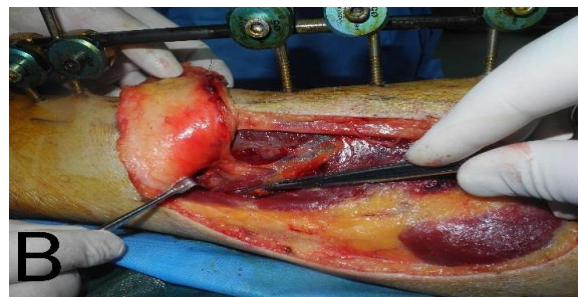
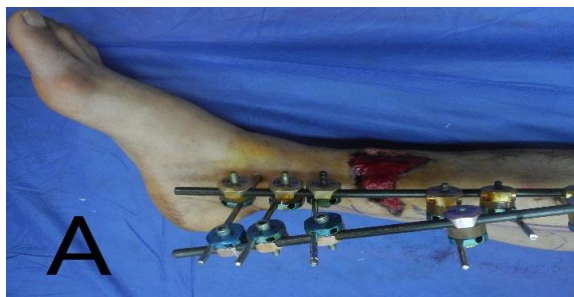

Figure (3): Peroneal artery perforator flap used for reconstruction of exposed Achilles tendon A; defect in distal leg posteriorly exposed Achilles tendon, B; flap harvesting islanding pedicle, C; flap rotation 180degree to the defect, D; six-month post operation.

Case no. 10: A 62-year-old male suffered a soft tissue defect and fracture of tibia in distal third of leg due to a traffic accident. After debridement, a posterior tibial artery based perforator flap measuring

approximately 5 cm × 14 cm was elevated from the ipsilateral lower leg. The flap was subsequently inset into the defect at 100 degrees based on the pivot of the perforator



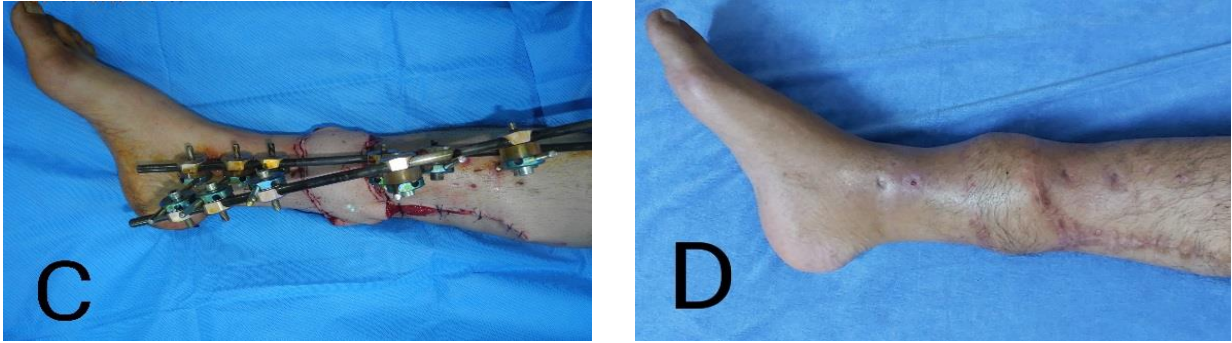


Figure (4): A, A defect with exposed tibial bone at fracture sit. B, Harvesting the posterior tibial artery perforator flap showing perforator (pivot point). C, Flap inset and direct closure of donor site D, Appearance 8 months after operation

Case 12: An 8-year-old female suffered a soft tissue defect in distal leg lead to exposed bone(tibia) in distal third due to a traffic accident. After radical debridement, anterior tibial artery based perforator flap measuring approximately 12 cm × 5 cm was elevated from the ipsilateral lower leg. The flap was subsequently inset into the defect at 110 degrees based on the pivot of the perforator. The donor site was closed by skin graft. Postoperative the flap survived totally without complications (Fig. 1).

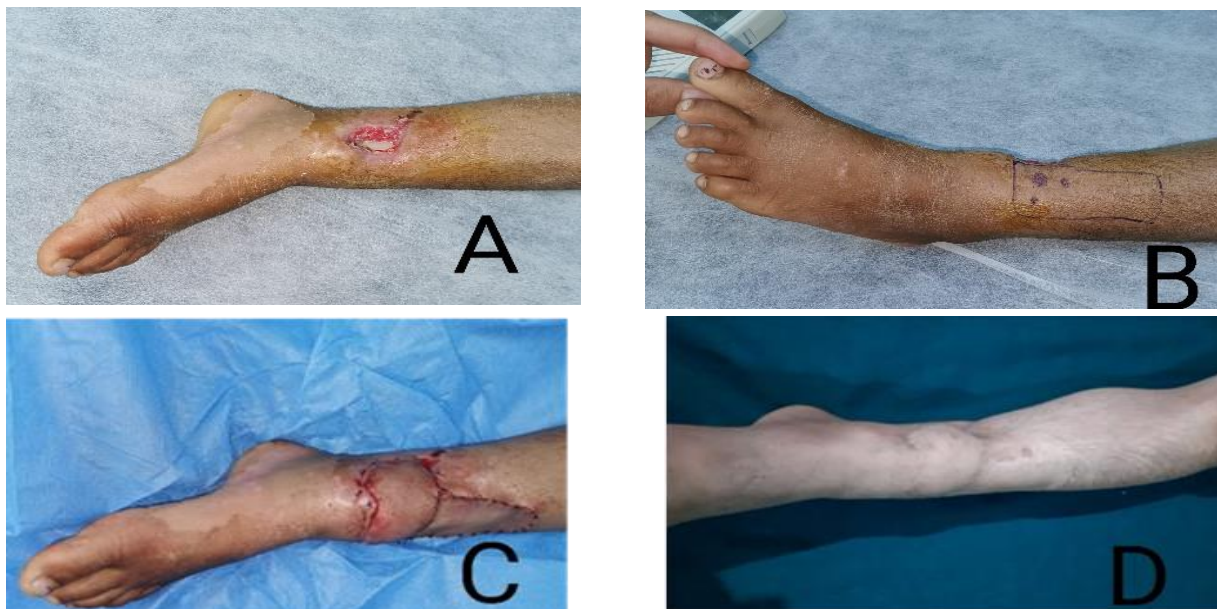


Figure (5): A, a defect in distal leg exposed bone. B, flap marking. C, flap inset. D, one-year post operation

Conclusions

Perforator flap could be a good reliable option for reconstructive surgeon to deal with wounds of lower limb ,ankle and foot in selected cases it is ideal for reconstruction of small to medium sized wound and have no or little role in large defect ,we will not recommend to use

Recommendation

We recommended identification of sizable perforator perioperatively, inset of flap in tensionless manor, not suturing

Conflict of interests

The authors recorded no conflict of interests

References

- 1.Georgescu AV. Propeller perforator flaps in distal lower leg: evolution and clinical applications. Arch Plast Surg. 2012;39(2):94-105.
2. Georgescu AV, Matei IR, Capota IM. The use of propeller perforator flaps for diabetic limb salvage: a retrospective review of 25 cases. Diabet Foot Ankle. 2012;3:10.3402/dfa.v3i0.18978.
3. Panse NS, Bhatt YC, Tandale MS. What is safe limit of the perforator flap in lower extremity reconstruction? Do

this flap in severe crushed wound, because of most of the time the perforators are within the zone of injury and inadequate soft tissue availability for reconstruction and it is better to shift to other reconstructive option.

edges under tension, positioning of leg postoperatively and lastly not using this flap in severally crushed leg.

we have answers yet? Plast Surg Int. 2011;2011:349357.

4. El-Sabbagh AH. Non-microsurgical skin flaps for reconstruction of difficult wounds in distal leg and foot. Chin J Traumatol. 2018;21(4):197-205.

5. Shen L, Liu Y, Zhang C, et al. Peroneal perforator pedicle propeller flap for lower leg soft tissue defect reconstruction: Clinical applications and treatment of venous congestion. J Int Med Res. 2017;45(3):1074-89.

6. Xiao W-A, Cao W-L, Tian F, et al. Fasciocutaneous flap with perforating branches of peroneal artery repairing soft tissue loss in anterior and middle parts of children's feet: A STROBE-compliant art. *Medicine*. 2018;97(31): e11351.
7. Yasir M, Wani AH, Zargar HR. Perforator Flaps for Reconstruction of Lower Limb Defects. *World J. Plast. Surg.* 2017;6(1):74-81.
8. Hyakusoku H, Yamamoto T, Fumiiri M. The propeller flap method. *Br J Plast Surg.* 1991;44(1):53-4.
9. Karki D, Narayan RP. The versatility of perforator-based propeller flap for reconstruction of distal leg and ankle defects. *Plast Surg Int.* 2012;2012:303247-.
10. Ibrahim RM, Gunnarsson GL, Akram J, et al. Color Doppler ultrasonography targeted reconstruction using pedicled perforator flaps-a systematic review and meta-analysis. *Eur. J. Plast. Surg.* 2018;41(5):495-504.
11. Yasir M, Wani A, Rashid H. Ergonomics and Biogeometry of Perforator/Propeller Flaps in the Lower Limb Reconstruction. *World J. Plast. Surg.* 2017;6(2):238-42.
12. Shin IS, Lee DW, Rah DK, et al. Reconstruction of pretibial defect using pedicled perforator flaps. *Arch. Plast. Surg.* 2012;39(4):360-6.
13. Cheng L, Yang X, Chen T, et al. Peroneal artery perforator flap for the treatment of chronic lower extremity wounds. *J Orthop Surg Res.* 2017;12(1):170-.
14. Shen L, Liu Y, Zhang C, et al. Peroneal perforator pedicle propeller flap for lower leg soft tissue defect reconstruction: Clinical applications and treatment of venous congestion. *J Int Med Res.* 2017;45(3):1074-89.
15. Rogers AD, Dos-Passos G. Propeller flaps for lower-limb trauma. *S. Afr J Surg.* 2014;52(4):105-7