



The efficacy of 20% salicylic acid solution versus intralesional MMR vaccine combination with 20% salicylic acid solution in treatment of plane wart

Banu Muhammed Jaza Noori* Ali Mozan Dhahir Elethawi**

Abstract

Background and objectives: Plane wart treatment is challenging; modalities such as cauterization and cryotherapy having a great probability to recur, as well as the risk of scarring, discomfort, and expensive costs. The goal of this study is to compare the efficacy of salicylic acid 20% superficial chemical peel alone to topical salicylic acid solution 20% combined with intralesional measles mumps rubella vaccine.

Methods: A therapeutic clinical trial conducted in outpatient department of “Shahid Nabaz Dermatology Teaching Center” a period from March to September of 2022. Fifty participants with plane wart were enrolled in this study, 27 female and 23 male. The participants were randomly divided into two groups, group- A 25 patients, received topical 20% salicylic acid solution with intralesional measles-mumps- rubella vaccine. Group B, received topical 20% salicylic acid solution alone. The total number of therapeutic sessions was six, and the solution was applied every two weeks and the measles-mumps-rubella vaccine was injected every fortnightly. Every two weeks, the effectiveness of the treatment was assessed by counting the number of lesions.

Result: Group A patients who were treated with intralesional measles mumps-rubella-vaccine combined with topical 20% salicylic acid solution showed complete clearance (24/25) with six sessions .group B patients treated with topical 20% salicylic acid solutions showed clearance (14/25) with six sessions. Lesions were significantly fewer in Group-A, which was statistically significant.

Conclusion: The intralesional measles mumps-rubella-vaccine combination with 20% topical salicylic acid solution and the 20% salicylic acid solution alone were both effective in clearing plane warts, however, intralesional measles mumps-rubella-vaccine combination with 20% topical salicylic acid solution can achieve higher response with fewer sessions .

Keywords: Chemical peel, MMR vaccine, plane wart, salicylic acid.

* M.B.Ch.B, KHCMS/ Dermatology trainee, Sulaymaniyah Dermatology Teaching Hospital, KRG, Iraq. Email: banunoori88@gmail.com. Corresponding author

** M .B. Ch. B, CABD, FIBMS, Professor of Dermatology , Consultant Dermatologist , ,Dermatology department / College of medicine/ Sulaymaniyah University. Email: Elethawi67@yahoo.com



Introduction

Human papillomavirus (HPV) infection results in a variety of skin abnormalities, including plane warts.^{1,2} It is more prevalent during childhood and adolescence.^{1,3} Adults are less prone than younger age groups to develop warts.^{2,3} Subtypes 3, 10, 28, and 41 are mostly to blame for plane warts.³⁻⁵ Plane warts are characterized by 2-4 mm shiny, smooth, flat, primarily flesh-colored papules. Lesions mostly affect the face, hand, and shins and can spread through Koebnerization.² Warts are often self-limiting in nature but may remain for years if left untreated but due to aesthetic considerations patients may seek medical treatment.⁶ There is currently no effective antiviral treatment for the human papillomavirus.⁷ Destroying the lesions is the cornerstone of plane warts treatment for this reason. There are many treatments for treating plane warts, including chemical preparations like trichloroacetic acid, salicylic acid, and retinoids, and other regimes. Additionally, physical techniques such as electro-cautery, cryotherapy, CO2 laser are effective in eliminating plane warts.^{5,6} Routine therapeutic techniques include the use of, cryotherapy, and electrocautery and acids are accompanied with pain, inconvenience, and a risk of scarring. Due to the cosmetic and psycho-social components of the face, these issues are more prevalent in individuals who have facial involvement. All current therapies have a response rate of roughly 50% and a recurrence rate of 25%–50%.^{1,3,5} Salicylic acid which is a beta-hydroxy acid that is used superficially as a topical peeling agent utilized in nowadays to treat a variety of facial conditions. It is a lipophilic substance that dissolves intercellular lipids that are affixed covalently to the cornified membrane that surrounds cornified epithelioid cells. Salicylic acid has been employed as a peeling agent in numerous research because of its anti-

hyperplastic and anti-inflammatory properties on the epidermis, as well as being suitable for dark skin types.⁸ Intralesional MMR vaccine may have the benefits of eliminating both treated and untreated remote warts without producing scarring, having a high safety profile, and having a presumed decreased recurrence rate.^{7,8} For intralesional immunotherapy, a variety of drugs are employed, with varying degrees of safety and effectiveness.¹¹ Additionally, because the MMR vaccine contains three separate antigens, the likelihood of the injected antigen is exceedingly sensitive, and the risk of allergy to the three antigens is quite low.⁹ Additionally, the MMR vaccine's side effect profile is minimal, with the most frequent side effects being mild flu-like symptoms and bearable soreness at the injection site. The aim of this study is to compare the efficacy of 20% salicylic acid solution alone with 20% salicylic acid solution combined with intralesional measles, mumps, and rubella vaccine for the treatment of plane wart.

Patients and methods

Fifty patients with plane wart participated in an open label comparison trial. Twenty three males and twenty seven females, they were clinically diagnosed by two skilled expert dermatologists; patients who presented to "Shahid Nabaz Dermatology Teaching Center's outpatient unit with cutaneous wart anywhere in the body other than anogenital area were included in the study. Included patients were patients with single or multiple extra-genital warts who had not received systemic or topical anti-wart treatment in the previous eight weeks. Exclusion criteria included previous hypersensitivity to MMR antigen, pregnancy/lactation, and presence of active infection, chronic disease immunosuppression and patients who were non-adherent to treatment. During the inspection, the total amount of plane wart in



every patient was recorded and an image was obtained. Following thorough clarification to each patient about the disease, its progression, and every aspect of the treatment, including the technique of application, technique of injection and side effects, verbal, written consent and ethical approval was obtained from Kurdistan Higher Council of Medical Specialties. The patients subdivided into two groups, each of 25 patients. Group A received topical SA solution 20% combined with intralesional MMR vaccine and group B received topical SA solution 20% alone. Injections were given every two weeks until a maximum of six injections. In the sessions, the affected region was disinfected using a 96% solution of alcohol, then allowed to dry. In accordance to the patient's group, 20% topical salicylic acid solution was applied to each lesion via cotton-headed stick and left to work for 5 minutes, after which the surface was cleaned with tap water and dried. When SA 20% solution was used in conjunction with MMR vaccination, the 20% SA solution was applied to each individual lesion, then 0.3 mL of MMR vaccine was intralesionally injected using an insulin syringe into the single largest wart. To achieve full remission, six treatments were given every two weeks. The number of lesions was counted and photographed every two weeks to objectively assess the patient response. All patients adhered to the treatment regime. Data was collected using a custom-made questionnaire, and SPSS version statistics software for social science analysis version 24. (Mean standard deviation) are descriptive statistics. To demonstrate the difference between different means, ANOVA, or analysis of variance, was employed. Statistical significance is determined by the p value being less than 0.05.

Result

This study includes 50 patients with a combined total of 1039 plane warts. Group-A included 25 patients with 633 plane warts, the mean age was (16.28±12.9), 7(28%) males & 18(72%) females. Group-B included 25 patients with 406 plane warts, the mean age group was (22.96±16.9), 16(64%) males & 9(36%) females. The mean duration of the lesions was 10.28±8.38 months in Group A and 9.68±6.4 months in Group B, (Table 1). In group A, prior to treatment, the patients had a total of 633 lesions; after the maximum of 6 sessions treatment, the total number of lesions was 10 (before treatment, the mean total number of lesions was 25.32±29.95, and after treatment 1.12±2.63), demonstrating a marked reduction in the total number of lesions following therapy with salicylic acid 20% solution +MMR vaccine (p=0.000). (Table 2). In group B, patients had a total of 406 lesions before treatment and 98 lesions remained after treatment (mean total number of lesions before therapy was 16.24±19.58 and after therapy 3.92±5.09 (p value =0.005). (Table 3). Overall, both groups A & B achieved high response (p-value=0.000 and 0.005, respectively), both are statistically significant but higher response was achieved with group A.



Table (1): Demographic features of groups A (topical salicylic acid 20%+intralesional MMR vaccine) and group B (Salicylic acid 20% alone).

Characteristics	SA & MMR	SA	Total	Significant Test	p-value
	(%)	(%)	(%)		
Age (years)					
< 10	9(36.0)	7(28.0)	16(32.0)	3.389	0.184
10 – 20	11(44.0)	7(28.0)	18(36.0)		
> 20	5(20.0)	11(44.0)	16(32.0)		
Mean ± S.D	16.28±12.9	22.96±16.9	50(100)	-1.565	0.124
Gender					
Male	7(28.0)	16(64.0)	23(46.0)	6.522	0.011
Female	18(72.0)	9(36.0)	27(54.0)		
Total	25(100)	25(100)	50(100)	100	

Table (2): Analysis of the number of lesions in the group A (salicylic acid 20% with intralesional MMR vaccine) and number of lesions in group B (salicylic acid 20%)

Number of lesions	SA & MMR				SA			
	No.of Patients	No.of lesions	Mean	S.D	No.of Patients	No.of lesions	Mean	S.D
after first session	25	512	20.4800	23.27574	25	397	15.8800	19.51563
after 2nd session	18	241	11.4000	15.75066	25	309	12.0000	16.28650
after 3rd session	8	92	5.2800	8.48783	23	222	8.8800	9.01073
after 4th session	2	40	2.7200	6.44541	19	168	6.7200	8.05461
after 5th session	1	10	1.4000	3.01386	17	127	5.0800	6.87338
after 6th session	1	10	1.1200	2.63502	14	98	3.9200	5.09019
F- test	9.405				3.548			
P-value	0.000				0.005			

Overall, both groups A &B) achieved high response (p-value=0.000 and 0.005, respectively), both are statistically significant

but higher response was achieved with group A.

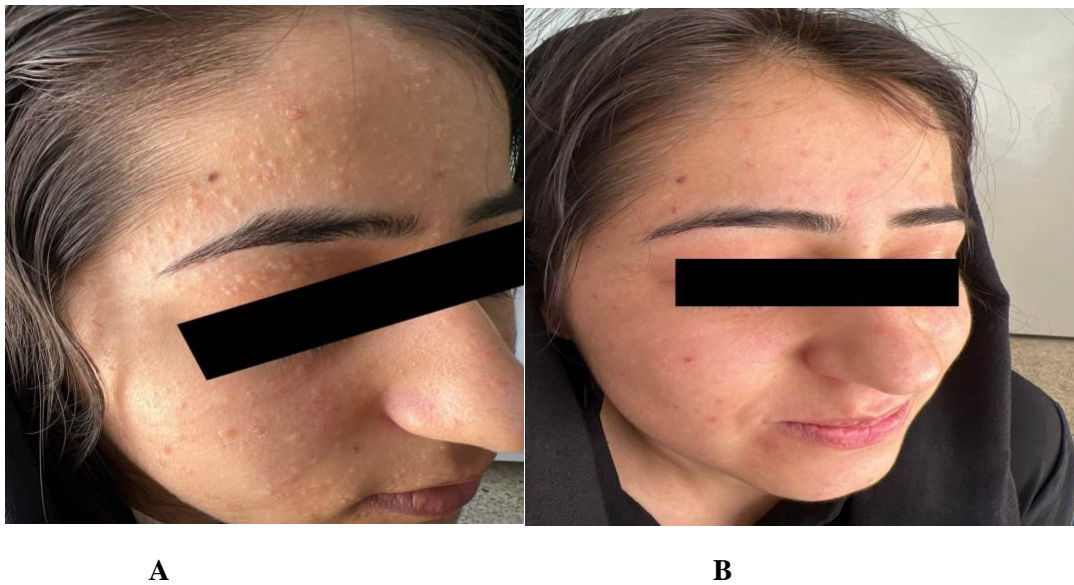


Figure (1): Patient received treatment using SA 20% solution + intralesional MMR vaccine, A: before therapy, B: after the fourth session.

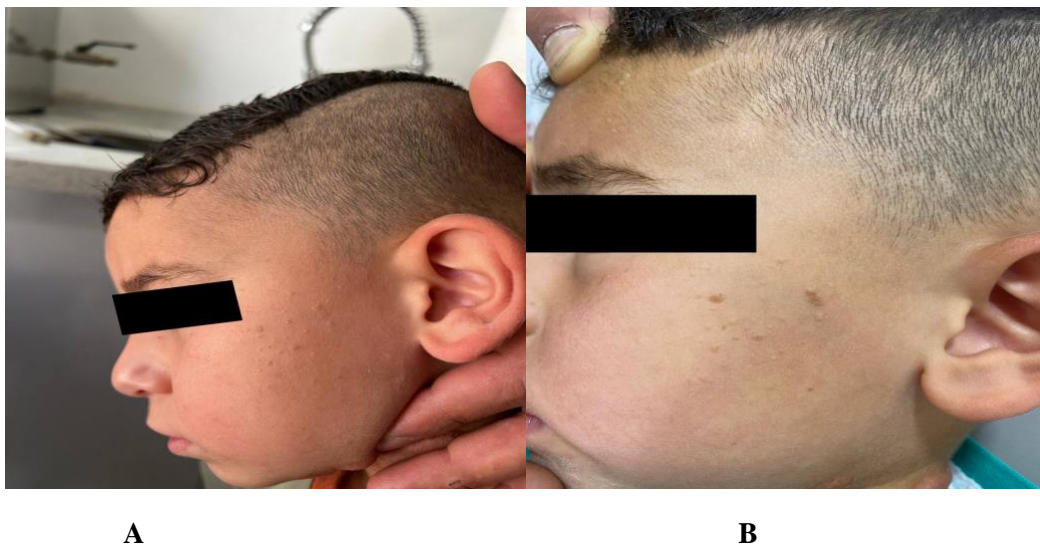


Figure (2): Patient received treatment using SA 20% solution, A: prior to therapy, B: following the fourth session.

Both group's side effect profile were minimal, group A most frequently patients experienced mild pain during injection. Other

side effects like burning, residual scarring and flu-like symptoms were not seen in any of the patients.

Discussion

Plane wart is a chronic condition caused by human papillomavirus infection. Self-healing occurs in some circumstances without the need for intervention. The patient's

immunological state influences spontaneous clearance. Immune system sensitization caused by the subject and the virus. Patients seek treatment due to aesthetic concerns which only involves the destruction of the



lesions.^{1,4}The purpose of this study is to evaluate the efficacy of 20% salicylic acid and 20% salicylic acid solution combination with intralesional MMR vaccination. Salicylic acid is frequently utilized in cosmetics because of its essential features; as desmolytic rather than keratolytic effect.¹³Treatment options include topical medications such as formic acid, salicylic acid, 5-fluorouracil perhaps in conjunction with cryotherapy, as well as curettage and laser therapy under local anaesthetic and others immunotherapeutic options including intralesional interferons, human papilloma virus vaccine, imiquimod.¹⁴ The most common preparation used in the treatment of warts are salicylic acid formulations. It is considered to function by exfoliating epidermal cells (keratolytic effect) and can be irritating at high concentrations. Immunotherapy is used in the treatment of warts by activating cell-mediated immunity. It has been demonstrated that intralesional MMR immunization causes wart regression through immunomodulation and immune system induction.¹⁵The average age of group A participants in our study was 16.28 ± 12.9 and females greater than males, while the average age of group-B was 22.96 ± 16.9 and males greater than females. There are numerous researches that used the preparations on which our study is based on. In group-A (salicylic acid 20% with intralesional MMR vaccine), we noticed a significant reduction in the number of wart lesions after therapy, ($p < 0.000$) while in group B, the reduction in the number of wart lesions following therapy (20% salicylic acid) was also significant, ($p < 0.005$). In group A, twenty-four of twenty-five patients had total clearance of lesions. (Salicylic acid 20% combined with intralesional MMR), Compared to Gamil et al., who showed 87% complete cure, 4.3% partial cure, and 8.7% no cure with MMR immunization in another study. The authors of the study discovered that the MMR vaccine had a therapeutic

effect in the treatment of warts.¹⁶ Which is greater than group-B (salicylic acid 20% alone), in which fourteen of twenty-five patients had complete clearance of lesions. Regarding side effects both groups of patient well-tolerated treatment with limited and minimal side effects such as erythema, a transient burning sensation, and soreness at the injection site in the group-A who received MMR vaccine. There was no swelling or irritation. The response to therapy with SA 20% combined with the intralesional MMR injection was shown to be much more effective than the response to treatment with 20% SA solution alone in group B patients. Because of the high SA concentration the therapeutic session must be administered only by experts in an office setting. These concentrations should never be used at home since they can cause major harm if patients use them.

Conclusion

When compared to topical salicylic acid 20% solution alone, applying salicylic acid 20% solution as a peeling agent in conjunction with intralesional MMR vaccine every two weeks for six sessions for treatment of plane warts proved to be more effective with fewer number of sessions. Yet, more therapeutic clinical researches in this field with a higher sample size and a longer time frame is recommended.

Conflict of interest

There were no conflicts of interest.

Reference

1. Jayaprasad S, Subramaniyan R, Devgan S. Comparative Evaluation Of Topical 10% Potassium Hydroxide and 30% Trichloroacetic Acid in the Treatment of Plane Warts. *Indian J Dermatol.* 2016; 61(6): 634–9.
2. Sterling J. Virus infections. In: Burns T, Breatnach S, Cox N, Griffith C, editors. *Rook's Textbook of Dermatology.* 8th ed.



West Sussex, UK: Wiley-Blackwell; 2004. 3339–41.

3. Hunter J, Savin J, Dahl M. *Clinical Dermatology*. 4th ed. New Jersey: Blackwell Publishing Company; 2008. 235–9.

4. Vali A, Ferdowsi F. Evaluation of the efficacy of 50% citric acid solution in plane wart treatment. *Indian J Dermatol*. 2007; 52:96–8.

5. Salih H, Fadeel B. Evaluation of isotretinoin gel and oral zinc sulphate in the treatment of plane warts. *J Fac Med Baghdad*. 2008; 50:448-50.

6. Al Obaidi H. Topical 5 fluorouracil versus topical tretinoin 0.05% in treatment of plane wart: randomized controlled comparative trial. *J.Biosc.Bioeng*.2013; 3: 368-72.

7. Nofal A, Nofal E, Yosef A, Nofal H. Treatment of recalcitrant warts with intralesional measles, mumps, and rubella vaccine: a promising approach. *Int J Dermatol*. 2015;54(6):667-71. doi: 10.1111/ijd.12480. Epub 2014 Jul 29. PMID: 25070525.

8. Signore RJ. *Candida albicans* intralesional injection immunotherapy of warts. *Cutis*. 2002 Sep;70(3):185-92. Erratum in: *Cutis* 2002;70(5):294. PMID: 12353895.

9. Kus S, Ergun T, Gun D, Akin O. Intralesional tuberculin for treatment of refractory warts. *J Eur Acad Dermatol Venereol*. 2005;19(4):515-6. doi: 10.1111/j.1468-3083.2004.01176.x. PMID: 15987315.

10. Raju J, Swamy AV, Nanjunda Swamy BL, Raghavendra KR. Intralesional measles, mumps and rubella (MMR) vaccine – An effective therapeutic tool in the treatment of

wart. *J Evid Based Med Healthc*. 2015;2:8548–51.

11. Sharquie KE, Al-Rawi JR, Al-Nuaimy AA, Radhy SH. Bacille Calmette-Guerin immunotherapy of viral warts. *Saudi Med J*. 2008 29(4):589-93. PMID: 18382805.

12. Perman M, Sterling JB, Gaspari A. The painful purple digit: an alarming complication of *Candida albicans* antigen treatment of recalcitrant warts. *Dermatitis*. 2005;16(1):38-40. PMID: 15996350.

13. Arif T. Salicylic acid as a peeling agent: a comprehensive review. *Clinical, Cosmetic and Investigational Dermatology*. 2015; 8: 455-61.

14. Abeck D, Tetsch L, Lüftl M, Biedermann T. Extragenital cutaneous warts - clinical presentation, diagnosis and treatment. *J Dtsch Dermatol Ges*. 2019;17(6):613-34. doi: 10.1111/ddg.13878. PMID: 31241843.

15. Gamil H, Elgharib I, Nofal A, Abd-Elaziz T. Intralesional immunotherapy of plantar warts: report of a new antigen combination. *J Am Acad Dermatol*. 2010;63(1):40-3. doi: 10.1016/j.jaad.2009.07.023. Epub 2010 May 11. Retraction in: *J Am Acad Dermatol*. 2010;63(5):907. PMID: 20462659.

16. Saini P, Mittal A, Gupta LK, Khare AK, Mehta S. Intralesional mumps, measles and rubella vaccine in the treatment of cutaneous warts. *Indian J Dermatol Venereol Leprol* 2016;82:343-5.