



## Mucocutaneous manifestation of COVID-19 infection in pediatrics age groups

Nina Jutiar Noory\* Mohammed Yousef Saeed Jaff \*\*

---

### Abstract

**Background and objectives:** It is known that the COVID-19 virus can induce a wide range of mucocutaneous symptoms. This study's main goal is to describe the variety of cutaneous symptoms caused by COVID-19 in the pediatric age category.

**Methods:** This is a retrospective case series study of pediatric patients with COVID-19 infection who were admitted to Jamal Ahmad Rashid Pediatrics Teaching Hospital in Sulaimaniyah city from September 2021 to March 2022. Moderate to severe Covid-19 infection was a factor in the patients' admissions. The patient's complete medical history was reviewed, which should include their age, gender, and any mucocutaneous manifestations, as well as their past medical history, family history.

**Results:** Three hundred twenty three cases of COVID-19 infection were enrolled in this study, 36 of them had skin manifestations. There were 56% female and 44% males. Their ages ranged from zero to 13 years. Skin manifestations were 13 patients (36%) had erythematomaculopapular rash, 8 patients (22%) had vesicular lesions, 7 patients (19%) had chilblain, 6 patients (17%) had urticaria and 2 patients (6%) had erythema multiforme. Overall 41 patients had Multisystem inflammatory syndrome in children (MIS-C), 11 patients had cutaneous manifestations (6 patients had erythematomaculopapular rash, 5 patients had vesicular rash), and 6 patients had mucosal lesions (4 patients had conjunctivitis, 2 patients had oral lesions).

**Conclusions:** We found that despite pulmonary and other systemic manifestation also corona virus infection can cause many mucocutaneous manifestation in pediatrics age groups. However, further studies with larger samples size and longer duration is recommended.

**Keywords:** COVID-19 infection, Mucocutaneous manifestations, Pediatrics age groups.

---

\*M.B.Ch.B, KHCMS dermatology trainee, Shahid Jabar dermatological teaching center, Sulaimani Directorate of Health, Sulaimaniyah, Iraq. Email [nina\\_jutiar989@icloud.com](mailto:nina_jutiar989@icloud.com)

\*\*M.B.Ch.B. FIBMS(dermatology), ISDS,ESLDC, Assistant Professor of dermatology , Department of Medicine , University of Sulaimani , Sulaimaniyah , Iraq, Email: [mohammad@derma-care.org](mailto:mohammad@derma-care.org)



## Introduction

Beta coronavirus is a single-stranded RNA virus that is coupled with a nucleoprotein, which is a spherical or pleomorphic enclosed particle with a capsid made of matrix protein.<sup>1</sup> Reduced ACE 2 activity can lead to renin-angiotensin system (RAS) dysfunction, an increase in vascular permeability, and the buildup of neutrophils. Rapid viral multiplication results in cellular death, which sets off a chain reaction of inflammatory responses and an increase in cytokines and chemokines.<sup>2,3</sup> The COVID-19 virus is very contagious, using fomites is one example of an indirect way of transmission, while aerosols, feco-oral, tears, saliva, semen, and mother-to-child transmission are examples of direct modes.<sup>4</sup> The most common sample for diagnosis is respiratory secretions, such as nasopharyngeal swabs, oropharyngeal swabs, throat swabs, sputum, and bronchoalveolar lavage fluid (BALF).<sup>5</sup> People of all ages can experience symptoms like urticaria, maculopapular rash, and vesicular rash. Cutaneous manifestations of chilblains, erythema multiforme (EM), and pediatric inflammatory multisystem syndrome (MIS-C) are more typical in pediatrics age groups with COVID-19 infection.<sup>6, 7</sup> Chilblains (Covid toe) is described as acral regions-specific inflammatory skin lesions, and is characterized by painful, itchy, erythematous, edematous macules, nodules, and sometimes ulcerated plaques on the dorsal surface of the toes.<sup>8</sup> Chilblain lesions of COVID-19, unlike the classical type, are seen equally in both sexes and there are no triggering factors. The lesions regress spontaneously between 2 to 9 weeks. Therefore, chilblains may be a disease that manifests later.<sup>9</sup> Erythema multiforme (EM) is characterized by acute, self-limiting hypersensitivity disorder with target lesions. Children with EM and COVID-19 infection

are usually asymptomatic or only experience minor gastrointestinal or respiratory symptoms.<sup>10, 11</sup> also there was vesicular exanthema which is a papulovesicular rash resembling chicken pox is the first vesicular rash identified in COVID-19 patients. Vesicular lesions arise earlier in the disease than the other cutaneous manifestations of COVID-19 disease. Diffuse, pruritic, monomorphic vesicles typically form on the trunk three days following the start of the initial respiratory symptoms and lasts for around eight days.<sup>12,13</sup> Urticaria is an itchy, isolated, elevated lesion that doesn't persist more than a day. Children with urticaria and COVID-19 infection largely exhibit asymptomatic behavior.<sup>14</sup> One of the most serious manifestation is Pediatric Multisystem Inflammatory Syndrome (MIS-C) which is characterized by fever in children, hyperemia in the conjunctiva and oral mucosa, mild facial edema, cracked lips, polymorphous rash varying from macular to maculopapular or morbilliform appearance on the trunk and spread over the extremities, desquamation of the fingertips with involvement of the cardiovascular, renal, respiratory, hematological, gastrointestinal, and neurological systems.<sup>15</sup> Early detection of skin and mucosal related condition is necessary because it may progress to severe cardiac involvement during viremia, which is the early clinical phase, may manifest as pericarditis, acute myocarditis, and sepsis-related cardiomyopathy, delayed presentations are coronary artery dilation/aneurysms, and late myocarditis, may occur in the weeks after the acute infection.<sup>16-18</sup> Lastly maculopapular rash is one of the most common skin signs seen during the Covid-19 epidemic. Distribution and presentation of maculopapular eruption ranged from diffuse scattered erythematous macules and papules which may coalescing into plaques.<sup>19</sup>

## Patients and methods

This is a retrospective case series study of pediatric patients with COVID-19 infection who were diagnosed and admitted by pediatricians to Jamal Ahmad Rashid Pediatrics Teaching Hospital in Sulaimaniyah city. This study was performed over 7 months from September 2021 to March 2022. The sample size was 323 cases, and only 36 of them had cutaneous findings, 41 out of these 323 case were diagnosed as MISC according to WHO criteria which include: Children and adolescents 0–19 years of age with fever  $\geq 3$  days and two of the following: First rash or bilateral non-purulent conjunctivitis or muco-cutaneous inflammation signs (oral, hands or feet). Second hypotension or shock. Third features of myocardial dysfunction, pericarditis, valvulitis, or coronary abnormalities (including ECHO findings or elevated Troponin/NT-proBNP). Fourth evidence of coagulopathy (by PT, PTT, elevated d-Dimers). Fifth acute gastrointestinal problems (diarrhoea, vomiting, or abdominal pain) and inflammatory markers were evaluated such as ESR, C-reactive protein, or procalcitonin. And no other obvious microbial cause of inflammation, including bacterial sepsis, staphylococcal or streptococcal shock syndromes. And evidence of COVID-19 (RT-PCR, antigen test or serology positive), or likely contact with patients with COVID-19.<sup>20</sup> Regarding inclusion criteria includes patients below 13 years for whom PCR test was positive. Test of nasopharyngeal or oropharyngeal swabs were used to determine the presence of a COVID-19 infection or those patients who had a history of close contact with positive PCR patients. On the other hand, patients above 13 years of ages and those with history of any dermatological diseases, congenital heart diseases, allergic drug reactions, cancers and those who were receiving

immunosuppressive therapy were excluded from the study. Indication of admission for the patients was moderate to severe Covid-19 infection especially those who have pulmonary or cardiac involvement and/or complaining of high grade fever. Diagnostic investigations, including polymerase-chain-reaction (PCR) test, D-Dimer, C - reactive protein (CRP), Chest X-ray were done for all of them. The study was approved by Kurdistan Higher Council Board of Medical Specialties; also we received an approval from pediatrics teaching hospital to review clinical files and investigation from medical records of all cases. I also received the registered phone numbers to call their parents and to review the detailed history of them which including age, gender, mucocutaneous manifestations (morphology, distribution either mucosa, scalp, hair, nails and palms/soles, duration of the lesions, associated symptoms) personal history of any chronic disease, history of drug administration and any allergy, past medical history and family history of any chronic diseases. The statistical software SPSS 29 is used for all statistical analysis.

## Results

The study included a total of 323 COVID-19 cases with swab confirmation who were younger than 13 years old. They were 180 females (56%) and 143 males (44%), as shown in figure (1). Ages ranged from day one to 13 years (8 patients less than 1 year, 12 patients from 1 to 5 years, 16 patients from 5 to 13 years), as shown in figure (2).

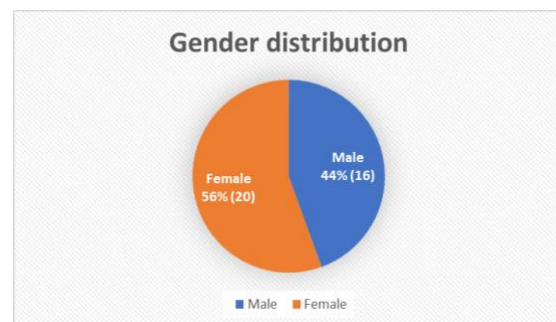
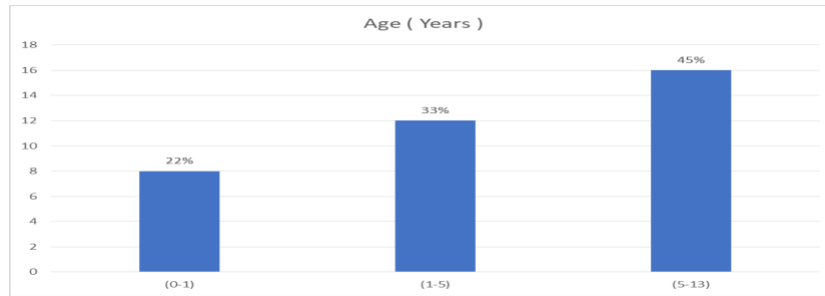


Figure (1) Genders of the patients



**Figure (2):** Ages of the patients

Out of 323 cases, 36 cases had mucocutaneous manifestations, and the most common skin presentation were maculopapular rash. Regarding clinical characteristics 13 patients (36%) had

erythematomaculopapular rash, 8 patients (22%) had vesicular lesions, 7 patients (19%) had chilblain, 6 patients (17%) and 2 patients (6%) had urticaria and erythema multiforme respectively as shown in table (1).

**Table (1):** Types of skin lesions

Type of skin lesion	Number	Percentage
Eythematomaculopapular	13	36%
Vesicular Rash	8	22%
Chill Blain	7	19%
Urticaria	6	17%
Erythema Multiforme	2	6%

In terms of duration of the of skin lesions, vesicular rash and urticaria lasted for about 2 to 3 days, erythematomaculopapular rash lasted 3 to 4 days, chilblain and acral

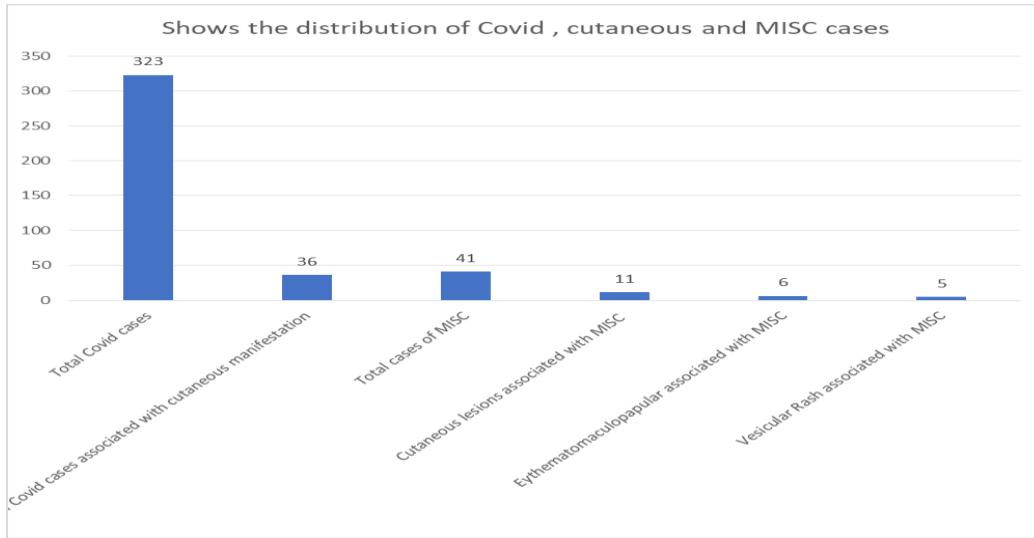
erythema multiforme lasted nearly 7 days, while generalized erythema multiforme had the longest duration which was 14 days as shown in table (2).

**Table (2):** Duration of skin lesions

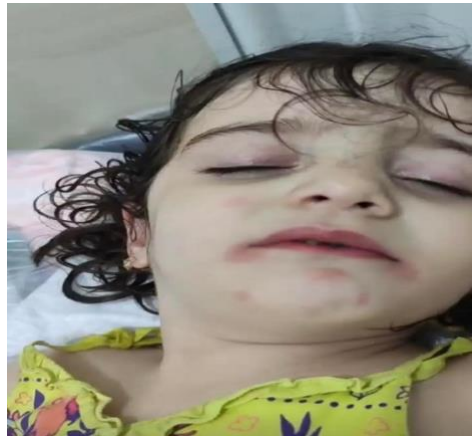Skin lesions	Duration ( days )
Eythematomaculopapular	(3-4)
Vesicular Rash	(2-3)
Chill Blain	(7-10)
Urticaria	(2-3)
Erythema Multiforme ( Generalized )	14
Erythema Multiforme ( Acral )	7

Overall 41 patients had MISC, 11 patients had cutaneous manifestations (6 patients had erythematomaculopapular rash, 5 patients had vesicular rash), and 6 patients had

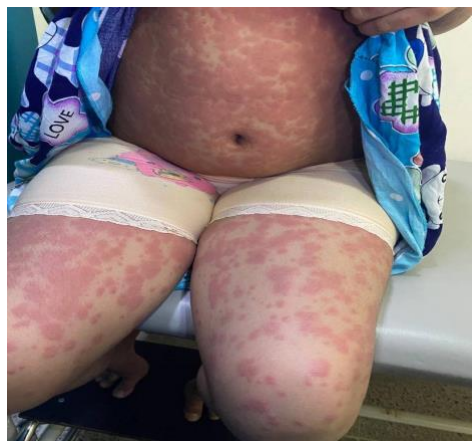mucosal lesions (4 patients had conjunctivitis, 2 patients had oral lesions) figure (3).



**Figure (3):** MISC associated with Covid-19 infection



**Figure (4):** 4 years old female with diffuse erythematous maculopapular lesions



**Figure (5):** 12 years old female with generalized Erythema Multiforme





## Discussion:

Since the SARS-CoV2 pandemic affected millions of people worldwide, its effects on health, the economy, and society have been devastating. Controlling this virus has become incredibly difficult as a result of asymptomatic transmission, a high rate of infection, and droplet infection of SARS-CoV2. Despite initial doubts, the dermatological interpretation of Covid-19 has proven to be complex and varied. Despite quickly developing research, the variety of Covid-19 skin manifestations is still largely unaccounted for. It is difficult to establish the actual prevalence of cutaneous symptoms in Covid-19 due to the lack of extensive prospective investigations. According to available literature, the frequency of dermatological lesions in Covid-19 is extremely variable.<sup>28</sup> Symptoms including urticaria, maculopapular rash, and vesicular rash can impact persons of different ages, a maculopapular eruption appears to be one of the Covid-19 patients' most frequent skin symptoms, although reports of maculopapular lesions linked to Covid 19 patients have been published, they have not yet been extensively evaluated.<sup>29</sup> Children are more likely to experience the cutaneous signs of SARS-CoV-2, including the maculopapular rash, vesicular rash, chilblains, erythema multiforme (EM), and multisystem inflammatory syndrome in children (MIS-C).<sup>6</sup> In the current study females were predominant; 56% of the patients were female. However, in the other studies, gender distribution was variable; in some studies, the males were predominant.<sup>21</sup> In addition, like our study, female were predominant in another study.<sup>22</sup> Most of the 16 patients in the current study were between the ages of 5 and 12 years old. Additionally, comparable results were found in other studies, which indicates that this age group accounted for the majority of instances.<sup>21</sup> <sup>23</sup> The most common skin manifestation in

our study was erythematous maculopapular rash, followed by vesicular (chicken pox-like) then chilblain-like lesions, while regarding erythema multiforme there was only 2 cases, in addition which is closer to this study there was maculopapular rash was predominant.<sup>21</sup> While in one further study majority of the cases presented with chilblain-like lesion (92.6%).<sup>24</sup> Also in one another study chilblain-like and erythema multiforme-like were predominant.<sup>25</sup> Regarding multisystem inflammatory syndrome in children (MIS-C) association with Covid-19 the similar study performed at pediatric cardiology department of university hospital of Sulaimanya found that there was 24 out of 32 cases were diagnosed as MIS-C associated with Covid-19 and it was 100% of the cases they had skin rash.<sup>16</sup> In contrast in one further study which was done at Qassim University, department of dermatology at Saudi Arabia; there were 2 cases report of MIS-C associated COVID-19 with morbilliform skin rash.<sup>17</sup> Although when we comparing mucocutaneous manifestation of pediatrics age groups with adult, there were two studies showed similarities between them in type of the skin lesions in adults with majority having morbilliform rash which was 55.7%.<sup>26,27</sup> However in our study there were no urticarial-like lesions were found however in one study which was done at Polly, MD/Dermatology/Duke Health in Florida, in a systemic review of 895 patients with COVID-19, 105 (12%) had urticarial lesions, which indicates that in adult urticaria common in patients with COVID-19, the clinical characteristics don't seem to differ from those with idiopathic urticaria and typically include generalized pruritic wheals and/or angioedema.<sup>26</sup>

## Conclusion

This article offers a thorough analysis of the cutaneous eruptions linked to SARS-CoV2. Patients with Covid-19 often experience respiratory symptoms, but other organs may also be involved as well as a variety of



cutaneous symptoms. All medical professionals must be familiar with the Covid-19 skin lesions because they may be related to the diagnosis, treatment, prognosis, and severity of the disease. Early detection of this eruptions may also aid in controlling the infection's further spread in the midst of this global epidemic. However, further studies with larger samples size and longer duration is recommended.

### Conflict of interest

There were no conflicts of interest.

### References

1. Nawaz MS, Fournier P, Shojaee A, Fujita H. Using artificial intelligence techniques for COVID-19 genome analysis. *Appl Intell.* 2021; 51(5):3086–103. Available from: <http://dx.doi.org/10.1007/s10489-021-02193-w/>
2. Yuki K, Fujiogi M, Koutsogiannaki S. COVID-19 pathophysiology: A review. *Clin Immunol.* 2020; 215(108427):108427. Available from: <https://www.sciencedirect.com/science/article/pii/S152166162030262X/>
3. Shah S, Akhade K, Ganguly S, Nanda R, Mohapatra E, Goel AK. Cutaneous manifestations associated with COVID-19 in children: A systematic review. *J Family Med Prim Care.* 2021; 10(1):93–101. Available from: <https://journals.lww.com/jfmpc/Fulltext/>
4. Karia R, Gupta I, Khandait H, Yadav A, Yadav A. COVID-19 and its modes of transmission. *SN Compr Clin Med.* 2020;2(10):1798–801. Available from: <http://dx.doi.org/10.1007/s42399-020-00498-4/>
5. Li C, Zhao C, Bao J, Tang B, Wang Y, Gu B. Laboratory diagnosis of coronavirus disease-2019 (COVID-19). *Clin Chim Acta.* 2020;510:35–46. Available from: <https://>

[www.sciencedirect.com/science/article/pii/S009898120303090/](http://www.sciencedirect.com/science/article/pii/S009898120303090/)

6. Larenas- D, Luna- J, Navarrete- EM, Rodríguez-N, Arias-A, Blandón-MV, et al. Cutaneous manifestations related to COVID-19 immune dysregulation in the pediatric age group. *Curr Allergy Asthma Rep.* 2021;21(2):13. Available from: <http://dx.doi.org/10.1007/s11882-020-00986-6/>
7. Seirafianpour F, Sodagar S, Pour A, Panahi P, Mozafarpour S, Almasi S, et al. Cutaneous manifestations and considerations in COVID-19 pandemic: A systematic review. *Dermatol Ther.* 2020;33(6):e13986. Available from: <http://dx.doi.org/10.1111/dth.13986/>
8. Alramthan A, Aldaraji W. Two cases of COVID-19 presenting with a clinical picture resembling chilblains: first report from the Middle East. *Clin Exp Dermatol.* 2020;45(6):746–8. Available from: <https://pubmed.ncbi.nlm.nih.gov/32302422/>
9. Romaní J, Baselga E, Mitjà O, Riera- N, Garbayo P, Vicente A, et al. Chilblain and acral purpuric lesions in Spain during covid confinement: Retrospective analysis of 12 cases. *Actas Dermosifiliogr.* 2020;111(5):426–9. Available from: <http://dx.doi.org/10.1016/j.adengl.2020.04.010/>
10. Andina D, Noguera- L, Bascuas- M, Gaitero- J, Alonso- JA, Escalada- S, et al. Chilblains in children in the setting of COVID-19 pandemic. *Pediatr Dermatol.* 2020;37(3):406–11. Available from: <http://dx.doi.org/10.1111/pde.14215/>
11. Garcia- G, Linares- L, Ródenas-Herranz T, Ruiz-Villaverde R. Chilblain-like lesions in pediatrics dermatological outpatients during the COVID-19 outbreak. *Dermatol Ther.* 2020 ;33(5):e13516. Available from: <http://dx.doi.org/10.1111/dth.13516/>
12. Mohan V, Lind R. Chilblains in COVID-19 infection. *Cureus.* 2020;12(7):e9245. Available from: <http://dx.doi.org/10.7759/cureus.9245/>



13. Sodeifian F, Mushtaq S, Rezaei N. Cutaneous manifestation of COVID-19: What have we learned an year into the pandemic *Actas Dermosifiliogr.* 2021 Nov 27. doi: 10.1016/j.adengl.2021.11.033. Epub ahead of print. PMID: 34866636; PMCID: PMC8626141.
14. Morey-Olivé M, Espiau M, Mercadal-Hally M, Lera-Carballo E, García-Patos V. Cutaneous manifestations in the current pandemic of coronavirus infection disease (COVID 2019). *An Pediatr (Engl Ed).* 2020;92(6):374-375. doi: 10.1016/j.anpede.2020.04.002. Epub 2020 Apr 27. PMID: 32341944; PMCID: PMC7183933.
15. Galván Casas C, Català A, Carretero Hernández G, Rodríguez-Jiménez P, Fernández-Nieto D, Rodríguez-Villa Lario A, et al. Classification of the cutaneous manifestations of COVID-19: a rapid prospective nationwide consensus study in Spain with 375 cases. *Br J Dermatol.* 2020;183(1):71–7. Available from: <https://pubmed.ncbi.nlm.nih.gov/32348545/>
16. Niu M, Jiang Q, Cao Y, Yang Q, Zhang Y, Li D et al. Tocilizumab in multisystem inflammatory syndrome in children (MIS-C)-summarized experiences, *J Eur Acad Dermatol Venereol.*2023;37(4):e443-e446.
17. Alhetheli G. Cutaneous manifestations of COVID-19 in pediatric patients: literature review. *Int J Res Dermatol*2021; 7:314-20.
18. Gunawan C, Angela A, Widysanto A. Urticarial eruption in coronavirus disease 2019 infection: a case report in Tangerang, Indonesia. *J Eur Acad Dermatol Venereol.* 2020;34(8):e372–3. Available from: <http://dx.doi.org/10.1111/jdv.16622/>
19. Abasaheed Elhag SA, Ibrahim H, Abdelhadi S. Angioedema and urticaria in a COVID-19 patient: A case report and review of the literature. *JAAD Case Rep.* 2020;6(10):1091–4. Available from: [https://www.jaadcasereports.org/article/S2352-5126\(20\)30553-1/pdf/](https://www.jaadcasereports.org/article/S2352-5126(20)30553-1/pdf/)
20. Lavery MJ, Bouvier CA, Thompson B. Cutaneous manifestations of COVID-19 in children (and adults): A virus that does not discriminate. *Clin Dermatol.* 2021;39(2):323–8. Available from: <http://dx.doi.org/10.1016/j.clindermatol.2020.10.020/>
21. Alshiyab DM, Al-qarqaz FA, Alhaje E, Mayou JA, Jaradat S, Asaad A, et al. Skin Manifestations Among Patients Admitted with COVID-19: A Cross-Sectional Study at a University-Based Tertiary Hospital in Jordan. *Clin Cosmet Investig Dermatol.* 2023;16:1331-1340 <https://doi.org/10.2147/CCID.S408958/>
22. Welsh EC, Alfaro Sanchez AB, Ortega Gutiérrez GL, Cardenas-de la Garza JA, Cuellar-Barboza A, Valdes-Espinosa RA et al. COVID-19 dermatological manifestations: results from the Mexican Academy of Dermatology COVID-19 registry. *Int J Dermatol.* 2021;60(7):879-881. doi: 10.1111/ijd.15544. Epub 2021 Apr 14. PMID: 33855708; PMCID: PMC8250812.
23. Kohli U, Lodha R. Cardiac involvement in children with COVID-19. *Indian Pediatr.* 2020;57(10):936–9. Available from: <http://dx.doi.org/10.1007/s13312-020-1998-0/>
24. Shams S, Rathore SS, Anvekar P, Sondhi M, Kancherla N, Tousif S, et al. Maculopapular skin eruptions associated with Covid-19: A systematic review. *Dermatol Ther.* 2021;34(2):e14788. Available from: <http://dx.doi.org/10.1111/dth.14788/>
25. Najafinejad M, Cheraghali F, Aghcheli B, Rajabi A, Barati L, Naziri H, et al. COVID-19 in pediatrics: Demographic, clinical, laboratory, and radiological characteristics of infected patients with SARS-CoV-2. *Front Pediatr.* 2021; 9:808187.
26. Polly S, Fernandez A. Common skin signs of COVID-19 in adults: An update. *Cleavel. Clin. J. Med.*2022, 89 (3) 161-7; DOI: <https://doi.org/10.3949/ccjm.89a.21126/>





27. Agarwal A, Das A, Panda M, Goyal J, Dash M. Cutaneous manifestations of covid-19 in pediatric population: A web based comparative study between the perspectives of dermatologists and pediatricians. *Cosmoderma*. 2022;2(39):39. Available from: <https://cosmoderma.org/cutaneous-manifestations-of-covid-19-in-pediatricpopulation-a-web-based-comparative-study-between-the-perspectives-of-dermatologistsand-pediatricians/>
28. Sawicka B, Aslan I, Della Corte V, Periasamy A, Krishnamurthy SK, Mohammed A et al. The coronavirus global pandemic and its impacts on society. *Coronavirus Drug Discovery*. 2022;(1)267–311. doi: 10.1016/B978-0-323-85156-5.00037-7. Epub 2022 Jun 10. PMID: PMC9217716.
29. Mohammed GF, Al-Dhubaibi MS, Atef L. Cutaneous Manifestations of Coronavirus Disease 2019: Skin Narratives and Dialogues. *J Clin Aesthet Dermatol*. 2022;15(5):E77-E81. PMID: 35642227; PMID: PMC9122281.